

# POST AURICULAR DERMOID CYST: A rare lump behind the ear.

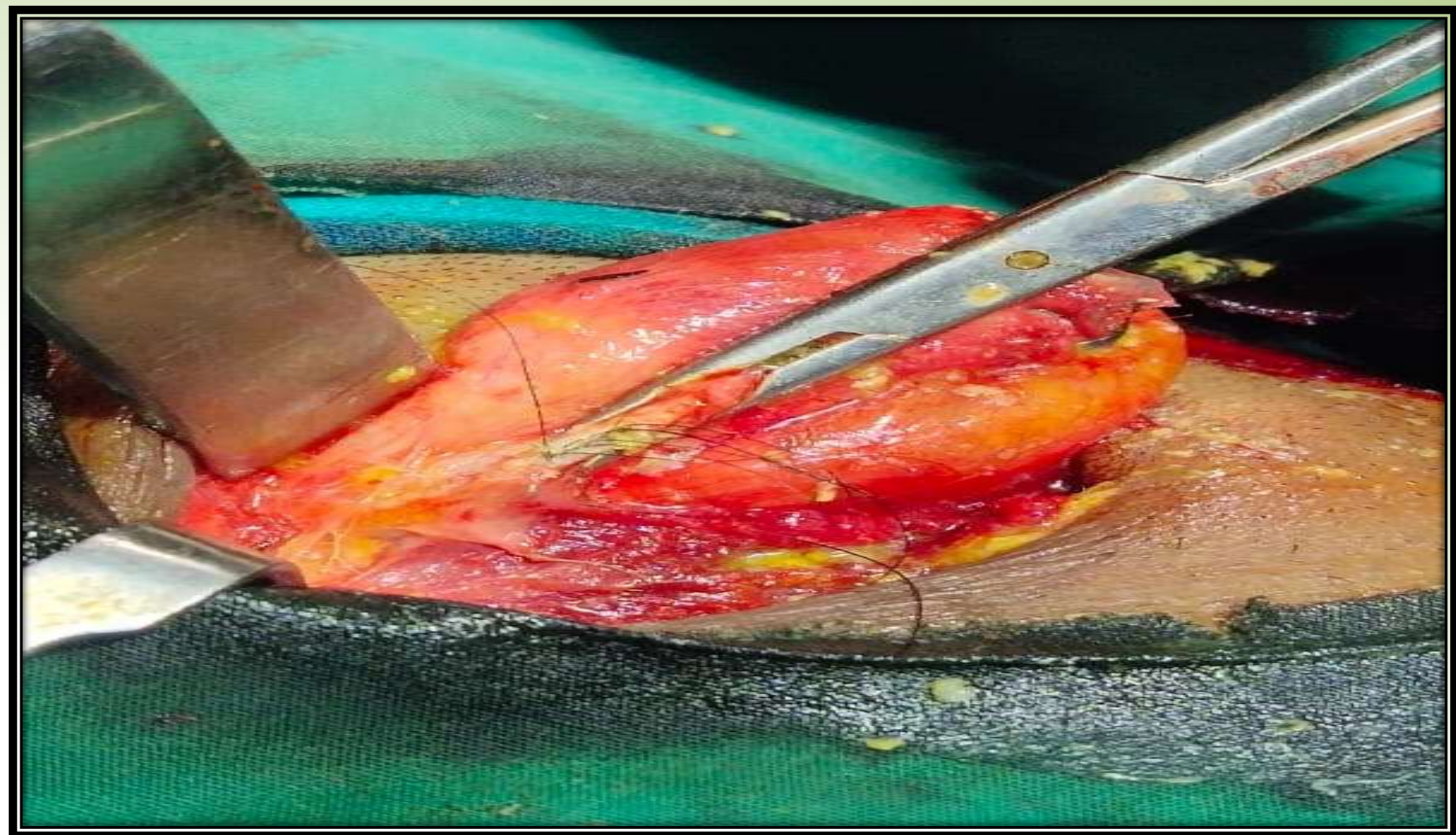DR.SAMEEKSHA MISHRA  
R.D Gardi Medical College, Ujjain

## BACKGROUND

Dermoid cysts are benign developmental anomalies. They are postulated to originate from the congenital inclusion of germ layers in the deeper tissues along the lines of embryonic fusion. The majority of dermoid cysts arise in the ovaries. Those occurring in the cervicofacial region are uncommon, accounting for about 7% of all dermoids. Dermoid cysts around the auricular region are rare.

## CASE REPORT

❖ A 35 years male came to the ENT OPD with chief complaints of swelling in left post auricular region since 01 year. Examination revealed regular, immobile and non-tender swelling of size 3x5 cms. Skin and temperature above the swelling were normal.

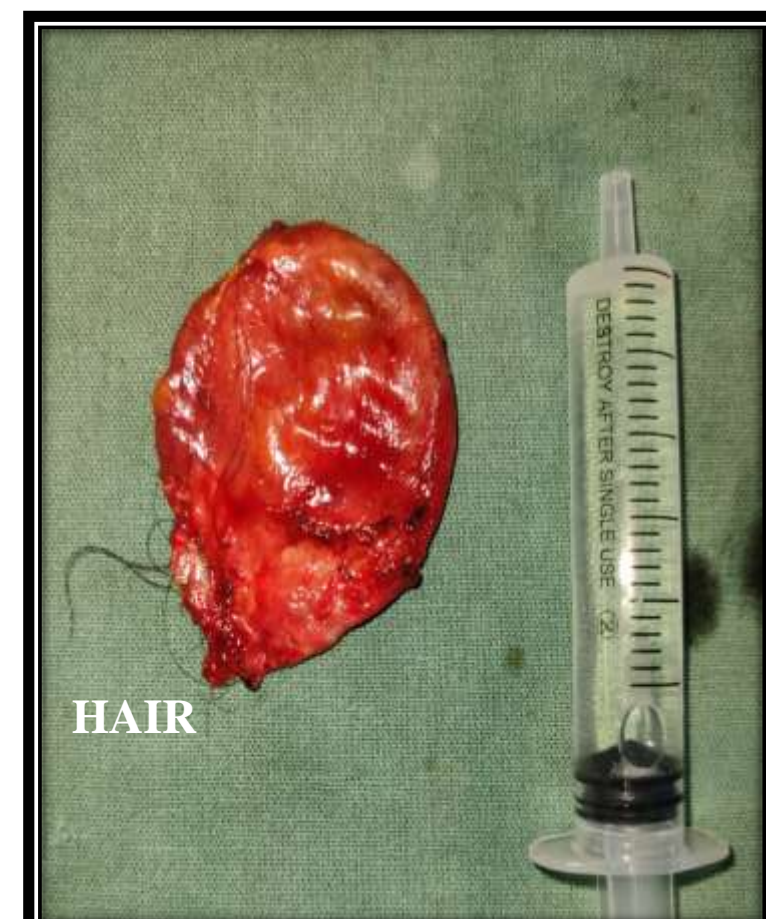
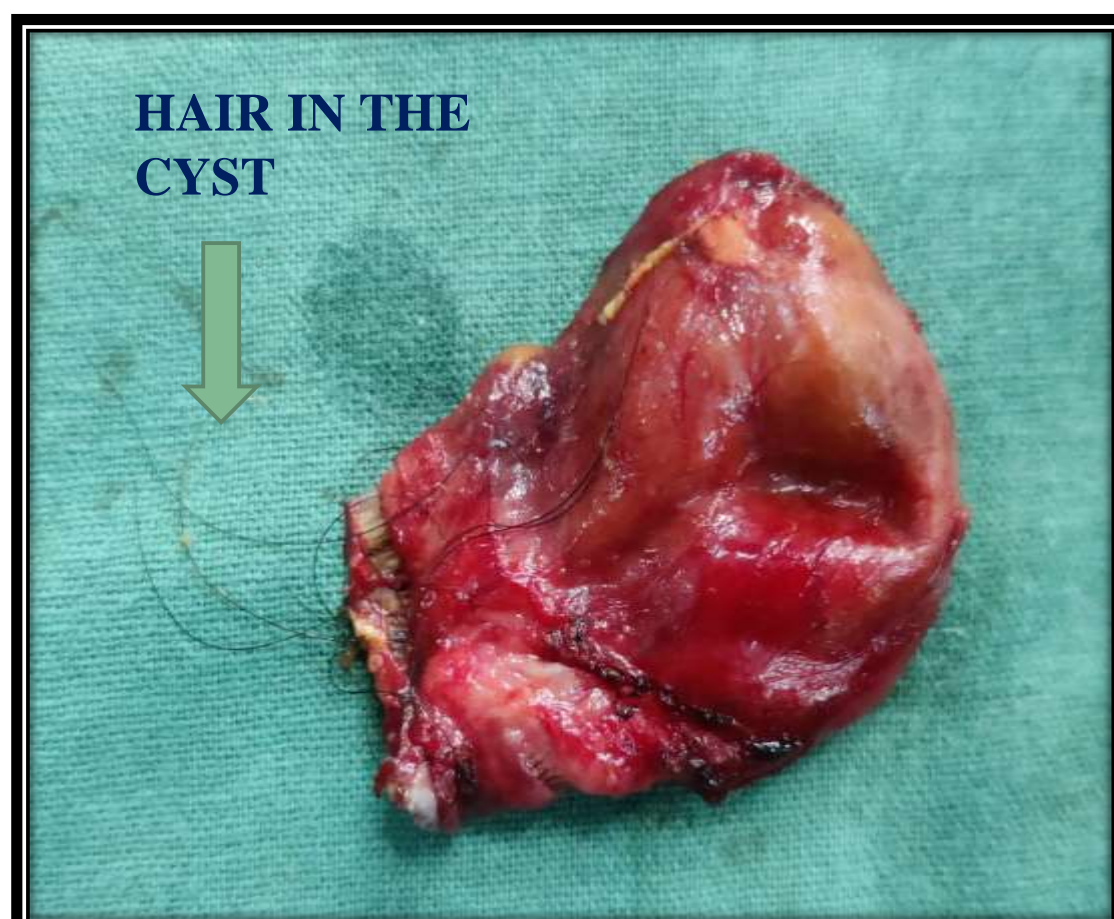
Cyst being excised.

## POST – OPERATIVE:

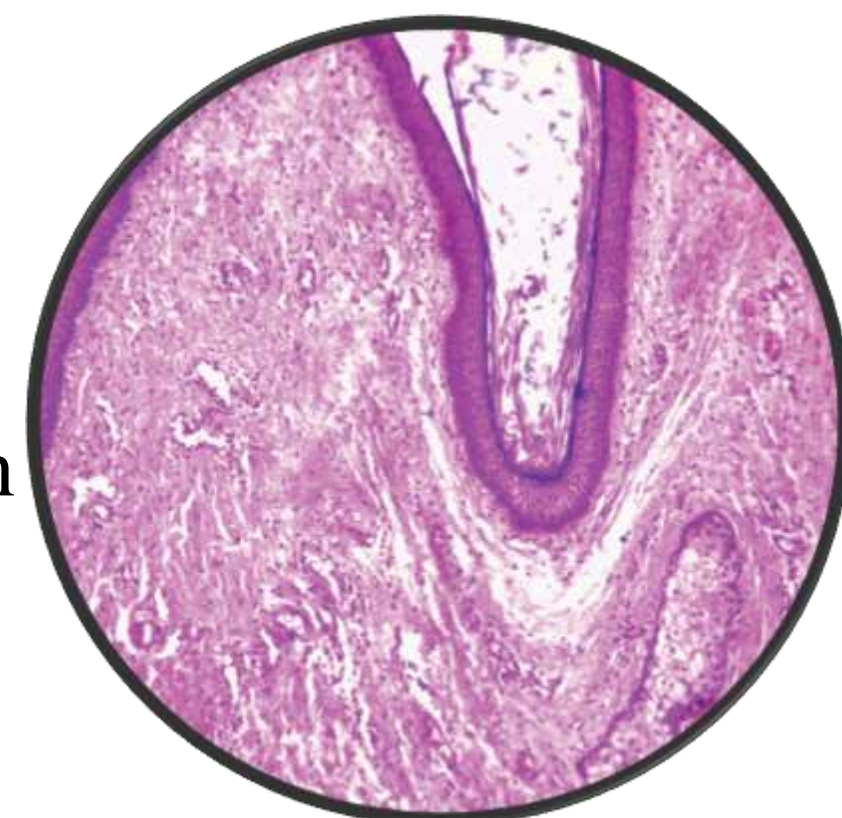
**Single, irregular, well circumscribed tissue**

**Piece with yellowish material oozing out of it along with a tuft of hair .**



## HISTOPATHOLOGY

Multinuclear giant cells and fragments of hair shaft are infiltrated in the cystic wall. Some keratin materials are seen in the intracystic area. These histologic findings were suggestive of the dermoid cyst.



## DIFFERENTIAL DIAGNOSIS:

LYMPH NODE ,EPIDERMAL /SEBACOUS/KERATINOUS CYST  
MASTOIDITIS,LIPOMA

## DISCUSSION

Dermoid cysts are benign developmental anomalies that occurred as a result of the sequestration of the skin along the lines of embryonic closure. Those occurring in the cervicofacial region are uncommon, accounting for about 7% of all dermoids and its presence in postauricular region is further exceptionally rare. Dermoid cysts can be divided into three types according to their histological characteristics, namely epidermoid, dermoid, and teratoid.

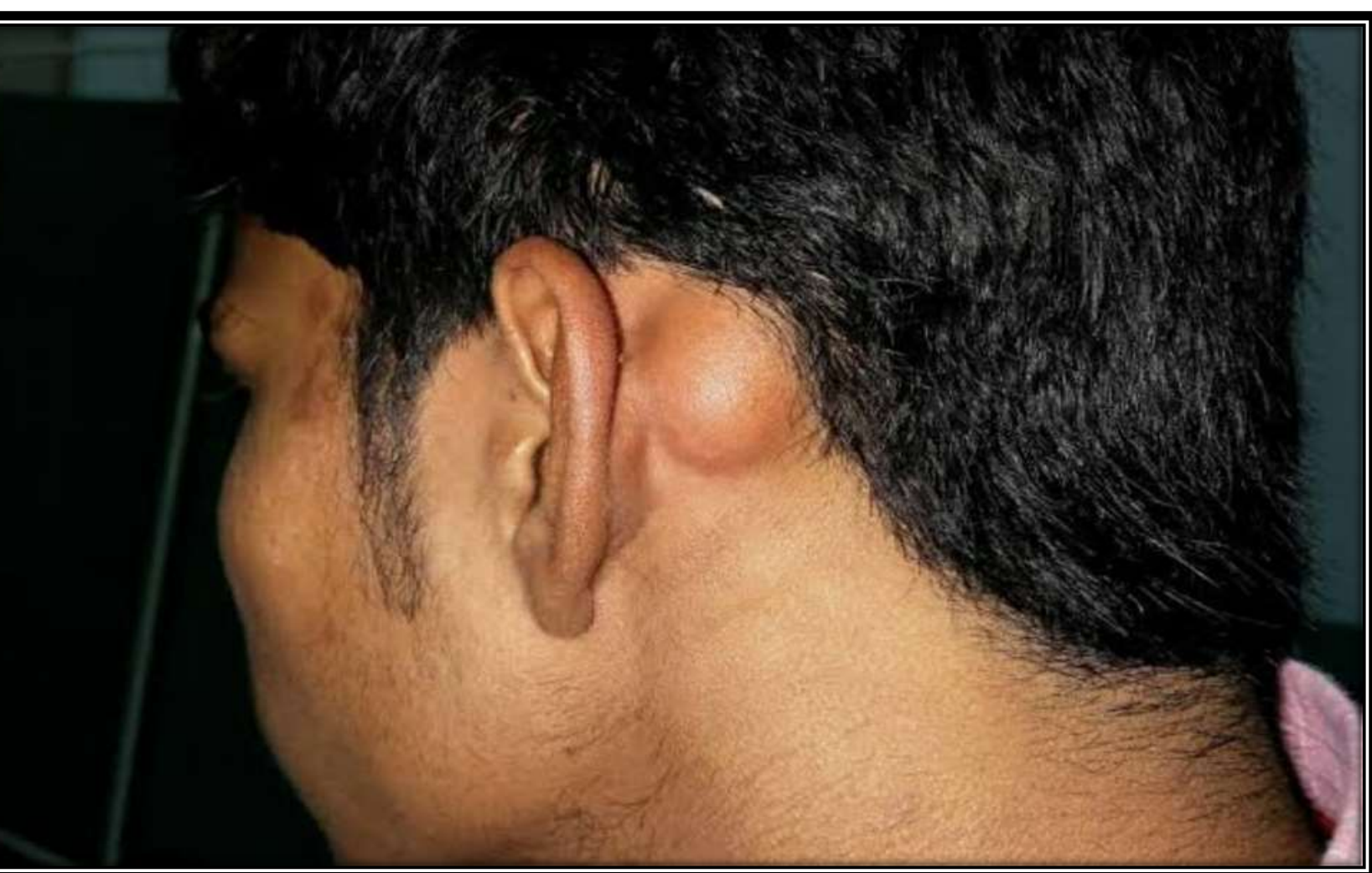## CONCLUSION

Patients with postauricular dermoid cysts usually seek medical advice for the cosmetic reasons because of the embarrassing look of the prominent unilateral or bilateral ears. The treatment of is complete surgical excision of the cyst wall. Incomplete removal may result in recurrence or infection. The prognosis is excellent without further complication.

## REFERENCES

[Dermoid Cyst in the Postauricular Area - PubMed \(nih.gov\)](#)  
[Post auricular dermoid cyst - A rare lump behind the ear | Request PDF \(researchgate.net\)](#)

[Sonographic Pictorial Review of Benign Palpable Paediatric Lumps: Head to Foot Asymptomatic Adults in Primary Care? \(e-mjm.org\)](#)

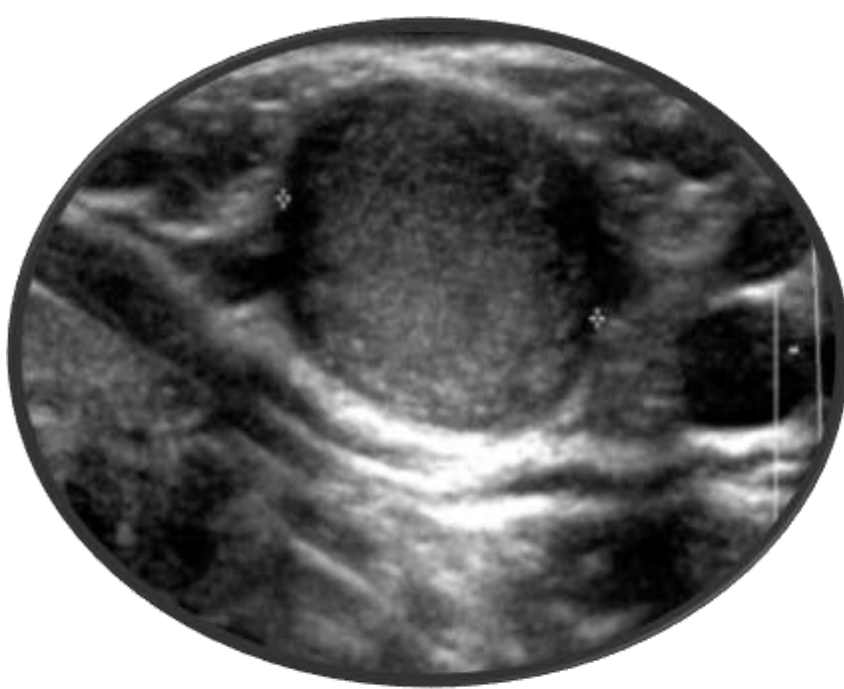


## INVESTIGATIONS

❖ Routine haematological investigations were normal.

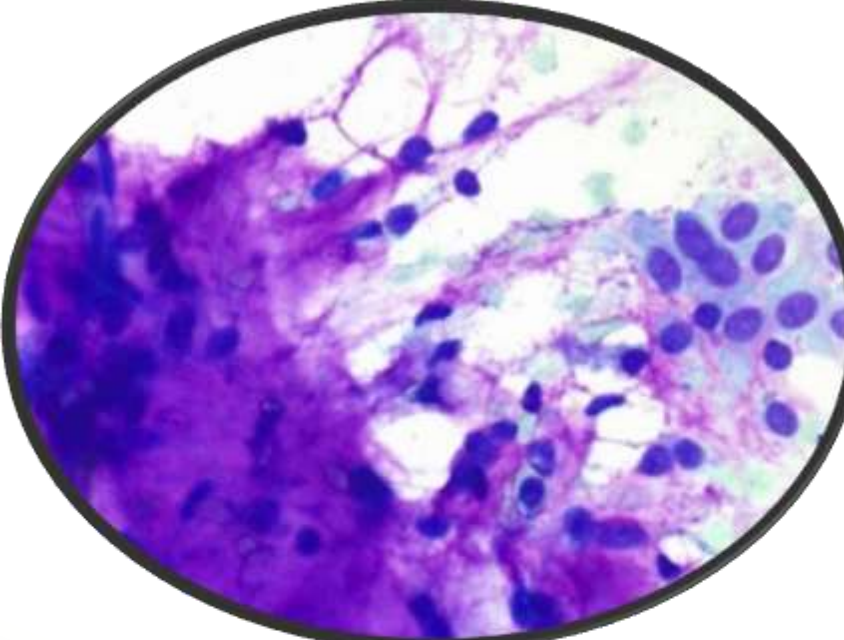
## **HIGH RESOLUTION ULTRASONOGRAPHY**

Appears as pseudosolid with mixed internal echoes due to their cellular and fat content, avascular. Fat globules within the lesion give rise to the '*sac of marbles*' appearance on CT or MRI that helps to confirm the diagnosis.



## **FINE NEEDLE ASPIRATION CYTOLOGY**

anucleated and nucleated squamous epithelium and keratin debris



## INTRA-OPERATIVE: Excision of left post auricular cyst done.

